

CASE REPORT

ACUTE CHOLECYSTITIS CAUSED BY *CLONORCHIS SINENSIS*

M Rohela¹, S Johari¹, I Jamaiah¹, I Init¹ and SH Lee²

¹Department of Parasitology, Faculty of Medicine, University of Malaya, Kuala Lumpur;

²Gleneagles Intan Medical Center, Kuala Lumpur, Malaysia

Abstract. We are reporting a case of a 43-year-old Chinese male from Hong Kong, who came to see a doctor complaining of acute onset of severe upper abdominal pain. A diagnosis of acute cholecystitis was made and an emergency cholecystectomy was carried out. On opening the common bile duct, lancet-shaped worms were seen emerging from it. About 45 adult worms were collected and sent to the Department of Parasitology University of Malaya for identification. The worms were identified as *Clonorchis sinensis*. After the operation the patient was treated with praziquantel and he had an uneventful recovery.

INTRODUCTION

The Chinese liver fluke, *Clonorchis sinensis* producing clonorchiasis was first seen in 1874 and described in 1875 by McConnell in the bile passages of a Chinese carpenter in Calcutta (Beaver *et al*, 1984). Clonorchiasis is common in countries in which infected freshwater fish is consumed raw or partially cooked. *Clonorchis sinensis* is widely distributed in China, Japan, Korea, Taiwan and Vietnam (Schmidt and Roberts, 2000). An estimated 19 million people are infected but the incidence has dropped markedly in recent years (Sun, 1988). Reports of this parasite outside eastern Asia involve infections in people who acquired it while visiting these places or by eating frozen, dried or pickled freshwater fish imported from endemic areas that harbor the encysted metacercariae. The prevalence may range from an average of 14% in cities such as Hong Kong to 80% in some endemic rural

areas (Schmidt and Roberts, 2000). In Malaysia it is seen on rare occasions in people who have a history of eating raw fish while traveling to endemic areas or who consumed imported raw fish. *Clonorchis sinensis* is a food-borne trematode which chronically infects the bile ducts and, more rarely, the pancreatic duct and gall-bladder of human beings and other fish eating mammals. The adult fluke passes operculated eggs into the feces. Once the eggs which contain fully developed miracidia reach fresh water they are ingested by an intermediate snail host. In the tissues of the snail the miracidium develops and multiply and the cercariae are released and penetrate fresh water fish which belong to the family Cyprinidae (Fig 1). Infection of humans occurs after eating pickled, salted, raw or dried fish infected with the metacercariae. The larvae are released in the duodenum and they proceed to enter the bile duct. The young flukes mature into adult worms in about one month. The entire life cycle can be completed in three months. The adult worm has a life-span of 20 to 25 years (Neva and Brown, 1994).

In endemic areas of clonorchiasis, patients have symptoms of tiredness, upper ab-

Correspondence: Dr M Rohela, Department of Parasitology, Faculty of Medicine, University of Malaya, 50603 Kuala Lumpur, Malaysia.

Tel: 603-7967-4751; Fax: 603-7967-4754

E-mail: rohela@ummc.edu.my

dominal discomfort, abdominal pain, dizziness, hepatomegaly and splenomegaly. In severe infections the most common complication is recurrent pyogenic cholangitis, also known as Oriental cholangio hepatitis. These patients have repeated attacks of fever, chills, abdominal pain, jaundice and hepatomegaly. They may die of hepatic failure if there is no surgical intervention (Daniel *et al*, 1997). In long-standing infections, cholangitis, cholelithiasis, pancreatitis and cholangiocarcinoma can develop. Particularly heavy infections can also result in narrowing or blockage of the bile ducts.

Diagnosis of clonorchiasis is based on the recovery of the characteristic eggs in the feces or in duodenal aspirate (Beaver *et al*, 1984). The eggs require differentiation from *Opisthorchis*, another species of liver fluke. The eggs of *Opisthorchis* closely resembles those of *Clonorchis sinensis*. Radiologic techniques provide indirect evidence of parasitic infection in the bile ducts. Noninvasive ultra sonography has gradually replaced cholangiography. Computered tomography has also been used in the diagnosis of clonorchiasis (Daniel *et al*, 1997). Praziquantel is the drug of choice. In the case of heavy infections complicated by obstructive jaundice requiring surgical intervention, cholecystec-



Fig 1–Grass carp, *Ctenopharyngodon idellus*, freshwater fish, a second intermediate host for *Clonorchis sinensis* that harbors the encysted metacercariae.




Fig 2–Adult worms of *Clonorchis sinensis* collected from the bile duct and gallbladder of the patient.

tomy and exploration of the common bile duct should be performed. Prognosis is good in light infections, but is less satisfactory in heavy or chronic infections (Beaver *et al*, 1984). Thorough cooking of all freshwater fish will assure protection of the human population (Beaver *et al*, 1984). Control of infection has been achieved in some areas by a combination of chemotherapy, health education and improved sanitation. Metacercariae are not killed by refrigeration, salting, or the addition of vinegar or sauce (Neva and Brown, 1994).

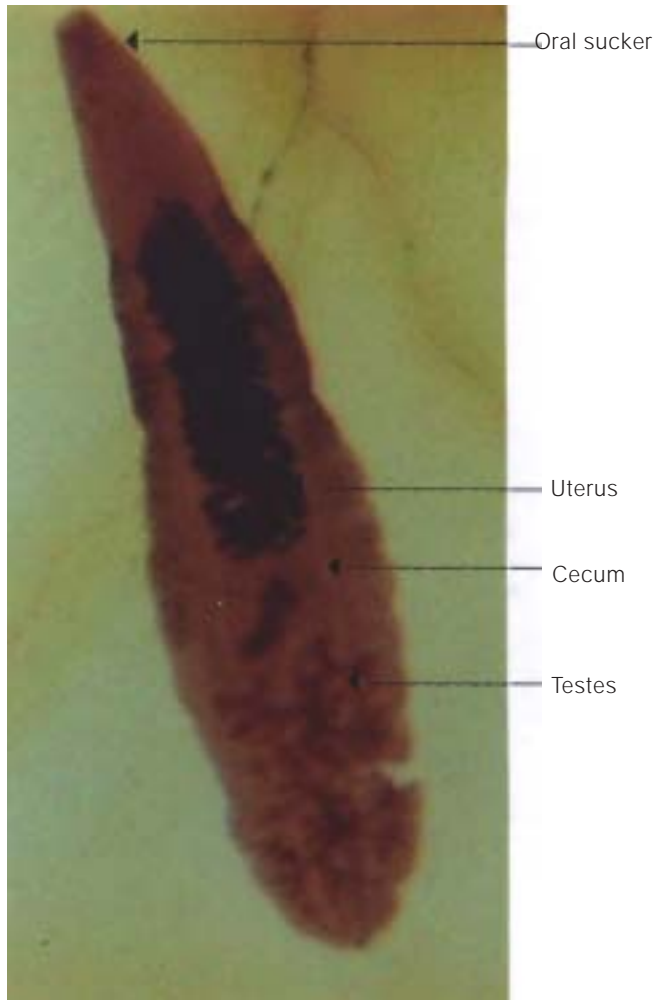


Fig 3—*Clonorchis sinensis*, adult specimen stained with carmine.

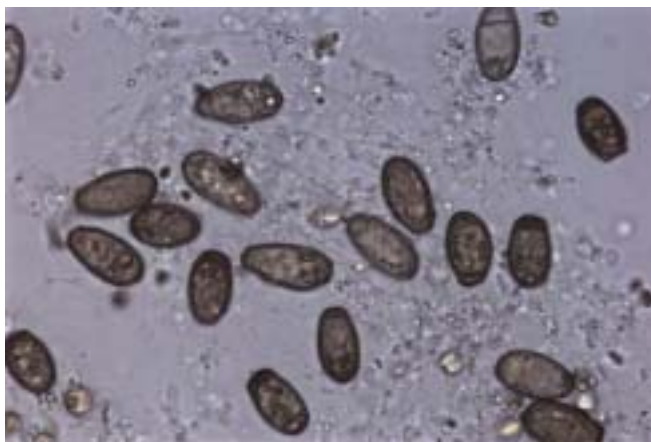

Fig 4—Eggs of *Clonorchis sinensis*, from the ruptured uterus (x40).

CASE REPORT

A 43-year-old Chinese man from Hong Kong who works as a TV film director in Kuala Lumpur, presented to a doctor at a Medical Center with acute onset severe upper abdominal pain. On admission, an ultrasound scan showed nodular lesions in the gallbladder and an enlarged dilated gallbladder which was consistent with acute cholecystitis. His liver function test was normal and he had no clinical jaundice. On the second day he developed jaundice and the pain became much worse. The patient underwent emergency cholecystectomy the same night. At operation, the liver was noted to be congested and friable, with features of fatty liver. The gallbladder was tense, dilated and edematous. On exploration of the common bile duct, lancet shaped worms were seen emerging from it, some of them were noted to be swimming in the washing solution. No stones were found. Lancet shaped adult worms were also found in parts of the gallbladder. Forty-five adult worms were sent to the Department of Parasitology, University of Malaya for identification (Fig 2). The worms were identified as *Clonorchis sinensis*, measuring an average of 18 mm long by 4 mm wide and appeared flat, transparent, attenuated anteriorly and rounded posteriorly. Branched testes was seen in the posterior part of the body (Fig 3). The eggs retrieved from the ruptured uterus measured an average of 28 μm long by 14.5 μm wide and were operculated (Fig 4). The histopa-

thology report showed no evidence of malignancy and histopathological findings of the gallbladder was consistent with acute-on-chronic cholecystitis and cholesterosis. On further questioning, the patient gave a history of traveling to China and Hong Kong one month before admission and had consumed raw fish while visiting these places. After the operation the patient was treated with praziquantel 25 mg/kg t.i.d. for 2 consecutive days. He had an uneventful recovery.

DISCUSSION

Attending medical doctors should consider clonorchiasis or opisthorchiasis as one of the differential diagnoses in patients presenting with abdominal pain, jaundice, hepatomegaly, enlarged gallbladder and a history of traveling to endemic regions.

In Malaysia, only 13 cases of clonorchiasis have been reported (Shekhar *et al*, 1995; Jamaiah and Rohela, 2005). The first reported human case of imported clonorchiasis was by Kuntz and Wells in 1962 in a Chinese man from Sabah (Shekhar *et al*, 1995; Lim, 2001). All the cases of clonorchiasis in Malaysia were imported cases, *ie* the patient acquired the infection while traveling to endemic areas or by eating raw fish which was imported into the country.

Bisseru and Lim (1969) noted that the potential intermediate hosts for the platyhelminth, the snail (*Melanoides tuberculata*) is present locally. However there have no reports of endemic disease. Perhaps the local snail is not a good host. Thus, it is unlikely that significant local transmission of the disease occurs in Malaysia (Lim, 2001).

With more Malaysians traveling abroad to countries endemic for *Clonorchis sinensis* or *Opisthorchis* and with an influx of tourists and immigrant workers from endemic regions into Malaysia, physicians and surgeons in Malay-

sia should be more aware of liver flukes causing hepatobiliary infection. More attention should be given to obtaining a good medical history, including information regarding food, travel, and regions where the patient has previously visited or resided. Those who have no history of traveling to endemic areas may give a history of eating imported raw fish. If infection by liver fluke is suspected then diagnosis can be confirmed by examination of stool specimens for the presence of the characteristic eggs and treatment can be instituted.

REFERENCES

- Beaver PC, Jung RC, Cupp EW. Clinical parasitology. 9th ed. Philadelphia: Lea and Febiger, 1984: 449-87.
- Bisseru B, Lim KC. *Opisthorchis viverrini* (Poirier, 1886) a trematode parasite of man in West Malaysia. *Trop Geogr Med* 1969; 21: 138.
- Daniel HC, Francis WC, David AS, Herbert JM, Ernst EL. Pathology of infectious diseases. Vol II. Connecticut : Appleton and Lange, 1997: 1351-60.
- Jamaiah I, Rohela M. Prevalence of intestinal parasites among members of the public in Kuala Lumpur, Malaysia. *Southeast Asian J Trop Med Public Health* 2005; 36: 68-71.
- Lim KG. A review of diseases in Malaysia. 2nd ed. Taiping: Lim Kean Ghee, 2001: 231-2.
- Neva FA, Brown HW. Basic clinical parasitology. 6th ed. Norwalk: Appleton and Lange, 1994: 226-44.
- Schmidt GD, Roberts LS. Foundations of parasitology. 6th ed. Singapore: McGraw Hill International Editions, 2000: 265-81.
- Shekhar KC, Nazarina AR, Lee SH, Pathmanathan R. Clonorchiasis/Opisthorchiasis in Malaysians - case reports and review. *Med J Malaysia* 1995; 50: 182-6.
- Sun T. Color atlas and textbook of diagnostic parasitology. New York: Igaku-Shoin, 1988: 246-54.