

POSSIBLE DISCOVERY OF CHINESE LUNG FLUKE, *PARAGONIMUS SKRJABINI* IN MANIPUR, INDIA

Shantikumar T Singh¹, Deven L Singh² and Hiromu Sugiyama³

Departments of ¹Microbiology, ²Physiology, Sikkim Manipal Institute of Medical Sciences, Gangtok, India; ³Department of Parasitology, National Institute of Infectious Diseases, Tokyo, Japan

Abstract. To obtain more information about *Paragonimus* species prevalent in Manipur, India, hundreds of freshwater crabs, *Potamiscus manipurensis*, were captured from mountain streams in the Motbung Mountains in Senapati District, from December 1997 to January 1998. Crab extracts were prepared by digestion, differential filtration, and sedimentation. The filtered sediments were critically examined under a stereomicroscope. Isolated *Paragonimus* metacercariae were used for morphological study and animal experimentation. Forty-seven metacercariae were fed orally to a 3-month-old male puppy of local breed; at autopsy 155 days after inoculation, 12 adult worms were recovered; 2 were free in the thoracic cavity and 5 pairs were in lung cysts. Two adult worms were flattened and fixed in 70% ethanol and the remaining worms were put directly into 70% ethanol and preserved until July 2005. The former 2 worms were stained with borax carmine for morphological study at Sikkim Manipal Institute of Medical Sciences, Sikkim, India. Two adult worms in the latter group were sent to the National Institute of Infectious Diseases, Tokyo, Japan, for morphological identification and DNA sequencing. The morphological features of the borax carmine-stained worms were characteristic of *P. skrjabini*, although no genetic material for PCR amplification and sequencing could be extracted from the worm.

INTRODUCTION

Paragonimiasis, or lung fluke infection, caused by one of several *Paragonimus* species, primarily affecting the lungs but also other organs and tissues of the body, is one of the most important parasitic zoonoses. It is widely distributed in the world, and is endemic in Asia, Africa, and Latin America. The infection is acquired by ingestion of raw or improperly cooked freshwater crabs or crayfish containing encysted metacercariae. Rarely, it can be transmitted by eating undercooked meat of paratenic hosts, such as pigs and wild boar infected with larval worms. In India, human paragonimiasis was unknown until 1982, when the first human case was reported from Manipur (Singh *et al.*, 1982). Subsequently, several cases of human paragonimiasis were described by Singh *et al.* (1986), indicating that the disease was endemic in many parts of Manipur. Recently, an endemic focus of human paragonimiasis was detected in Arunachal Pradesh, another northeast state of India (Narain *et al.*, 2003). Now, paragonimiasis is increasingly recognized as a public health problem, especially in the northeast region of India (Fig 1). Although there are many unsettled questions about the taxonomic identification, life cycle, and pathobiology of *Paragonimus* species

prevalent in India, *P. westermani* has been presumed to be the only species infecting animals and humans. The present study describes the discovery of a lung fluke species in India that was morphologically identified as *P. skrjabini*. This lung fluke species was reported to occur in China and has been regarded as an important species causing human infections (Chen, 1959; Chung and Tsao, 1962).

MATERIALS AND METHODS

Several hundred freshwater crabs, *Potamiscus manipurensis* (Fig 2) were collected from mountain streams in Motbung, Senapati District, Manipur, from December 1997 to January 1998 (Fig 1). After morphological examination, crab extracts were prepared by mincing, digestion with artificial gastric juice consisting of 1 g of pepsin (Sigma Aldrich) in 1 liter of 0.7% hydrochloric acid, and overnight incubation at 37°C. Filtered sediments were obtained by passing the digested extract through differential filters of wire sieves (mesh size 1 mm-700 µm) and rinsing with clean tap water 4-5 times. The final filtered sediments were prepared in physiological saline. The sediments were critically examined for *Paragonimus* metacercariae using a stereoscopic microscope. The metacercariae isolated from the sediments were transferred in glass vials containing physiological saline and stored at 4°C until further study.

A 3-month-old male puppy of local breed was experimentally infected orally with 47 metacercariae.

Correspondence: ST Singh, Department of Microbiology, Sikkim Manipal Institute of Medical Sciences, 5th Mile Tadong, Gangtok 737102, India. Tel: 91-3592-270535; Fax: 91-3592-231496 E-mail: slg_sminms@sancharnet.in

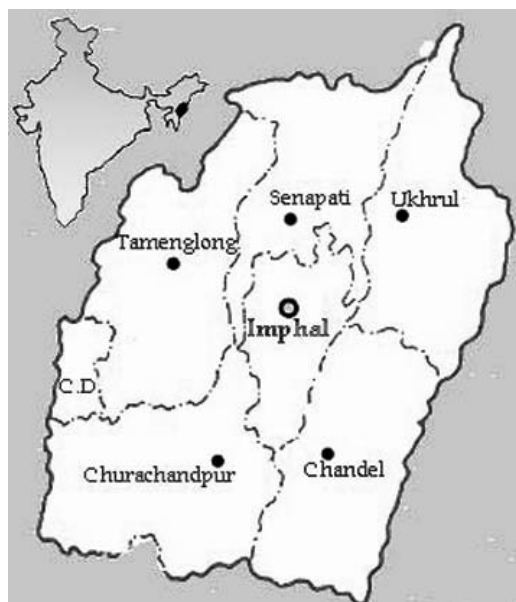


Fig 1- Map of India (upper left) indicating the location of Manipur State in the Northeast Region. Manipur State (center) comprises the capital city, Imphal, and 6 districts, including Senapati District, where *Paragonimus*-positive freshwater crabs were captured.




Fig 2- Freshwater crabs, *Potamiscus manipurensis*, playing a role as the second intermediate host of *P. skrjabini* in Manipur State, India.

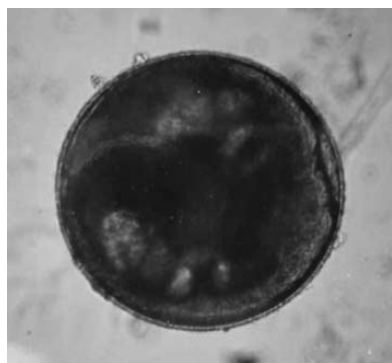


Fig 3- Microphotograph of a metacercaria.

Autopsy was performed on day 155 post-infection. The abdomen and thorax were cut open and examined thoroughly for pathological lesions and worms. The recovered worms and eggs were cleared in physiological saline and preserved in 70% ethanol for morphological identification and molecular characterization. Two worms were flattened between two glass slides, fixed in 70% ethanol, and the remaining worms were preserved in 70% ethanol until July 2005. The former 2 worms were stained with borax carmine and examined at Sikkim Manipal Institute of Medical Sciences, Gangtok, India; the 2 worms in the later group were sent the National Institute of Infectious Diseases, Tokyo, Japan, for parasitological confirmation and molecular characterization by PCR and DNA sequencing.

RESULTS

The metacercariae harvested from crabs were spherical in shape and possessed an 'I'-shaped excretory bladder (Fig 3). The average diameter of the inner cysts of the metacercariae measured 416 μ m. Some metacercariae were excysted during examination (Fig 4).

Autopsy on the test puppy showed hemorrhagic spots and brownish inflammatory patches on the surfaces of the lungs and pericardium. Two freely migrating worms were found in the thoracic cavity. In the lungs, 7 worm cysts were observed, of which 5 contained pairs of worms with reddish brown viscous fluid. Microscopy examination of the fluid, as well as brownish patches on the surface of the lungs, revealed numerous golden brown operculated eggs. The other 2 cysts, which localized deep in the lung parenchyma and consisted of thick fibrous walls, had no worm. Therefore, a total of 12 worms were recovered from the test puppy.

The unstained worms were spindle-shaped and measured 8-9 mm in length and 3-4 mm in width (Fig 5). The borax carmine-stained worms showed that the ovary ramified intricately like ginger stem, and the testes elongated like stumpy masses with fewer branches (Fig 6). The ovary and testes were almost the same in size. The ventral sucker, situated about the anterior third of the body, was slightly larger than the oral sucker. The vitellariae were thickly distributed from the lateral sides through the body to the midline. The uterus, faintly stained, was seen to contain eggs. The seminal vesicle and seminal receptacle were filled with spermatozoa. The cuticular spines were singly spaced and some showed splitting (Fig 7).

On the basis of the morphological characters of

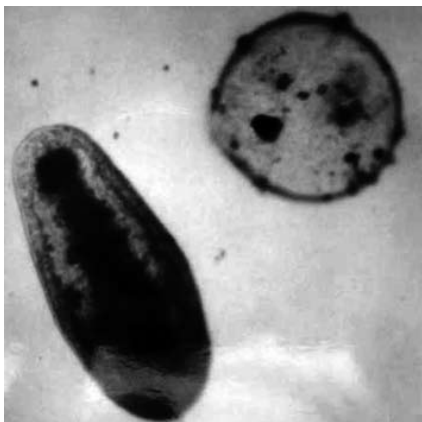

Fig 4- Microphotograph of a larva excysted from a metacercarial cyst.

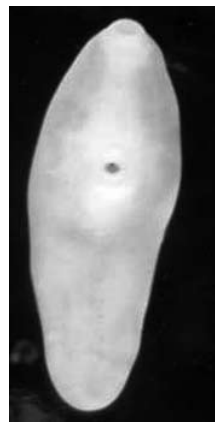

Fig 5- Photograph of an adult worm preserved in 70% ethanol.

the metacercariae and adult worms, the specimens were identified as *Paragonimus skrjabini*. No genetic material for PCR amplification and sequencing could, however, be extracted from an adult worm preserved in 70% ethanol.

DISCUSSION

In 1990, the first Indo-Japan joint research work on *Paragonimus* and paragonimiasis was launched in Manipur. The study aimed primarily to determine the crab host and *Paragonimus* species prevalent in various localities in Manipur. Freshwater crabs, *Potamiscus manipurensis*, collected at different localities, were found naturally infected with more than one type of *Paragonimus* metacercariae. All of the adult worms recovered from the experimentally infected animals were morphologically different from *P. westermani*. Unexpectedly the morphological features of the metacercariae and adult worms in the present study resembled those of *P. skrjabini*, which was first described from a viverrid, *Paguma larvata* (Smith) in Guangzhou City, Guangdong Province, China (Chen, 1959). Immature specimens have been reported from human cases of cutaneous paragonimiasis in the same province (Chung and Tsao, 1962), suggesting *P. skrjabini* is a zoonotic pathogen. Similar clinical forms have also been observed in Manipur.

The occurrence of another Chinese species *P. hueitu'ngensis* in Churachndpur District of Manipur was described by Singh (2002). Li and Chen (1992) proposed that *P. hueitu'ngensis* is synonymous with *P. skrjabini*, and one of the polymorphic forms of the *P. skrjabini* complex. The geographical distribution of the 2 species was thought restricted to China until our previous and present reports from Manipur, India.

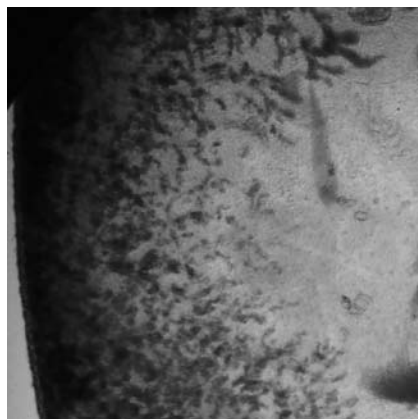


Fig 6- Microphotograph of a borax carmine-stained adult worm showing the ovary and testes.



Fig 7- Microphotograph of the cuticular spines.

Considering the widespread distribution of the infected crab host and its popularity among crab-eaters in endemic areas, this species may be one of the important causes of paragonimiasis in animals and humans in Manipur. To confirm this speculation, more detailed life-cycle studies, morphological characterization, and molecular phylogenetics of this lung fluke is needed. The study will provide valuable epidemiological data on the distribution of the species, pathogenesis and phylogenetic relationships with species of the same genus occurring in Asian countries.

ACKNOWLEDGEMENTS

The authors thank the Director, Regional Institute of Medical Sciences, Imphal, Manipur and the Dean, Sikkim Manipal Institute of Medical Sciences, Tadong, Gangtok, India, for allowing us to conduct the study. We also thank Dr Achariya Rangsiruji, of Srinakharinwirot University, for her invaluable suggestions and review of the manuscript. The financial assistance provided to HS by the Tokyu Foundation for Better Environment is gratefully acknowledged.

REFERENCES

- Chen H-T. The occurrence of a new type of *Paragonimus* and some clinical problems related to lung flukes in China. Annual report 1958. Guangzhou: Chung Shan Medical College, 1959:192-3 (in Chinese).
- Chung H-L, Tsao W-C. *Paragonimus westermani* (Szechuan variety) and a new species of lung fluke: *Paragonimus szechuanensis*. Part II. Studies on the clinical aspects of *Paragonimus szechuanensis*: a new clinical entity. *Chin Med J* 1962;81:419-34.
- Li Y-S, Chen Y-Z. Discriminations on some species of *Paragonimus* from China. *Wuyi Sc J* 1992;9:269-75. (in Chinese, English abstract).
- Narain K, Devi KR, Mahanta J. *Paragonimus* and paragonimiasis - a new focus in Arunachal Pradesh, India. *Curr Sci* 2003;84:985-52.
- Singh I, Singh B Ng, Devi Subadani S, Singh Mohen Y, Razaque M. Pulmonary paragonimiasis. A case report. *Indian J Chest Dis Allied Sci* 1982;304-6.
- Singh TS, Mutum SS, Razaque MA. Pulmonary paragonimiasis: clinical features, diagnosis and treatment of 39 cases in Manipur. *Trans R Soc Trop Med Hyg* 1986;80:967-71.
- Singh TS. Occurrence of the lung fluke *Paragonimus hueitu'ngensis* in Manipur, India. *Chin Med J (Taipei)* 2002;65:426-9.