

A VERY RARE CAUSE OF MILK OF CALCIUM GALLBLADDER: CARCINOMA OF THE AMPULLA OF VATER

CHIAMCHIT KALAYASIRI, DIREK DAMRONGSAK*, ORAPAN CHEARANAI and KASEM LIMVONGSE**

Department of Medicine, *Department of Radiology and **Department of Surgery,
Siriraj Hospital, Mahidol University, Bangkok, Thailand.

INTRODUCTION

Milk of calcium bile or limy bile is a well known entity which was first reported by Churchman in 1911 and by Balachandra and Simarak in 1968, but its definite aetiology is still uncertain (Besic *et al.*, 1965; Marquis and Densler, 1970). Its common cause is believed to be stone, in the cystic duct with obstruction (Rothman, 1965; Paul and Juhl, 1966; Balachandra and Simarak, 1968; Marquis and Densler, 1970). In 1955 and 1957, Cohen and Simmonds respectively, reported cases of milk of calcium bile in the common bile duct which were produced by common duct stones. To our knowledge, milk of calcium gallbladder caused by ampullary carcinoma has not yet been reported. The purpose of this paper is to report such a case with a review of the literature.

Milk of calcium bile contains a high percentage of calcium carbonate (Simmonds, 1957; Paul and Juhl, 1966; Whitehouse, 1967; Kerley, 1969). This lime, less often, is calcium phosphate or calcium bilirubinate (Besic *et al.*, 1965; Hodges and Whitehouse, 1965). The term "milk of calcium bile" (Kalkmilchgalle) was used by Volkmann in 1935 (Kornblum and Hall, 1935; Simmonds, 1957). Knutsson in 1933 reported 12 cases under the title of "limy bile". The milk of calcium gallbladder is non-functional, obstructed and chronically inflamed, with hypertrophic muscular wall. The consistency of the limy bile varies considerably from a semiliquid to a paste, a putty or even a solid

stone (Simmonds, 1957; Besic *et al.*, 1965; Bockus, 1965; Hodges and Whitehouse, 1965).

Roentgenographic findings: Milk of calcium bile produces an opaque shadow on a plain film simulating that in a cholecystogram. In addition to the amorphous calcium carbonate, the gallbladder may contain one or more stones. The condition is often associated with stone in the cystic duct (Paul and Juhl, 1966; Kerley, 1969). Most observers cited that the density and size of the gallbladder did not change following a cholecystography and fat meal (Kornblum and Hall, 1935; Balachandra and Simarak, 1968) but this was not necessarily true; Besic *et al.*, (1965) reported a case of milk of calcium gallbladder which showed contractility and diminution in size with simultaneous visualization of the cystic duct after ingestion of fat.

CASE REPORT

A 34-year old Thai policeman was admitted to Siriraj Hospital on February 21, 1969 with a complaint of having had intermittent jaundice for approximately six months. Two months prior to admission, he developed progressive jaundice, pruritus, indigestion, easily tired and gradual loss of weight. The colour of the urine was dark and the stool was pale. The patient experienced no abdominal pain. The past history was non-contributory.

Physical examination revealed an anaemic, markedly jaundiced male with hyposthenic

build. Several sweat retention papules were noted on the thigh. His body temperature was 37°C, pulse rate 96/minute, respiration rate 20/minute, blood pressure 110/70 mm Hg. The liver was 3 finger breath below the right costal margin without tenderness, with smooth surface and firm consistency. The spleen was not palpable.

Laboratory investigations on admission revealed haemoglobin 11.0 gm%; white blood count 4,500/c.mm with 70% polymorphonuclears and 30% lymphocytes; bilirubin 1 minute, 13.00 mg% 30 minute, 25.00 mg%; albumin 3.4 gm%, globulin 5.3 gm%; SGOT 306 sigma units; SGPT 170 sigma units; cholesterol 1,100 gm%; alkaline phosphatase 13.6 B.U.; sugar 82 mg%; serum amylase 111 units; sodium 138 mEq/L; potassium 3.8 mEq/L; bicarbonate 24.0 mEq/L; chloride 94.0 mEq/L; BUN 7 mg%; creatinine 0.9 mg%; uric acid 2.7 mg%;

Peritonescopy on February 21, 1969 disclosed enlarged, bile stained and oedematous liver with smooth surface. The gallbladder was slightly enlarged. These evidences were suggestive of extrahepatic duct obstruction. Numerous irregular blood vessels were present over the distal portion of the gastric antrum indicating to the possibility of the pathology at or under this region.

Roentgenography of the right upper quadrant of the abdomen on February 21, 1969 revealed faint opaque material of the size of the gallbladder, similar to "milk of calcium bile". Intermixed were multiple small lucent shadows, indicating the presence of small gallstones (Fig. 1).

Surgical exploration revealed a slightly enlarged liver with bile stain. The gallbladder was moderately distended and rigid without gallstones. The common bile duct was dilated, measuring approximately 2.5 cm in diameter. Neoplastic growth was found at the ampulla of Vater, associated with regional

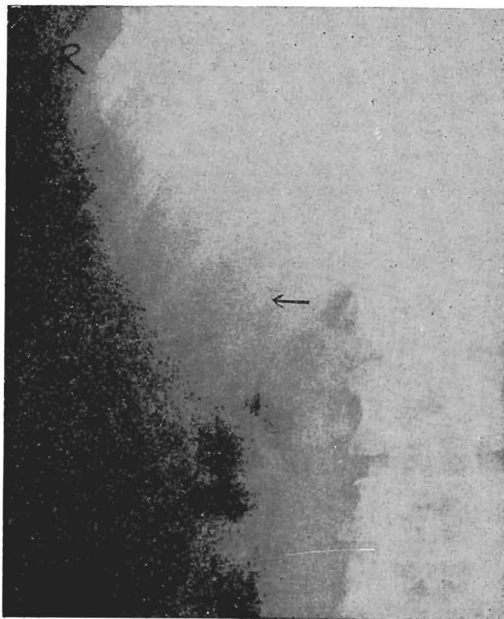


Fig. 1—The plain film of the gallbladder region demonstrates radiopaque material in the gallbladder which is normal in size. Multiple minute lucent shadows are present in the fundus of the gallbladder.

lymphadenopathy. The common bile duct, duodenum and the head of the pancreas as well as the regional enlarged lymph nodes were removed. Anastomosis of the remaining organs was performed in the usual procedure. The immediate post-operative course was uneventful and the patient was subsequently discharged from the hospital on March 18, 1969 with marked clinical improvement.

Pathohistological diagnosis was adenocarcinoma of the ampulla of Vater.

DISCUSSION

The cause of milk of calcium gallbladder in this instance was the obstruction of the biliary system at the level of the ampulla of Vater by adenocarcinoma, but how the limy bile was formed was not exactly known. It is also difficult to explain why there is selective opacification of the gallbladder but not the

common duct. It is possible that limy bile was produced in the gallbladder and had not migrated to the common bile duct. The other suggestion may be marked dilatation of the common duct resulting in dilution of calcium carbonate in the bile which is inadequate to produce radiopaque shadow in a plain X-ray film. However, the true explanation awaits further investigations.

SUMMARY

A very rare case of milk of calcium gallbladder, produced by carcinoma of the ampulla of Vater, is reported. The gallbladder was faintly opacified by limy bile without opacification of the common duct. Explanations of this observation were presented.

REFERENCES

- BALACHANDRA, T. and SIMARAK, S., (1968). Milk of calcium bile: Report of 3 cases. *Chiengmai Med. Bull.*, 7 : 9.
- BESIC, L.R., KRAWZOFF, G. and TIESENGA, M.F., (1965). Limy bile syndrome. *J.A.M.A.*, 193 : 245.
- BOCKUS, H.L., (1965). *Gastroenterology*, V. 3, 2nd ed. W.B. Saunders Company, Philadelphia and London. p. 777.
- CHURCHMAN, J.W., (1911). Acute cholecystitis with large amounts of calcium soap in the gallbladder. *Johns Hopkins Hospital Bull.*, 22 : 223.
- COHEN, O.H., (1955). Limy ductus choledochus. *Radiology*, 65 : 78.
- HODGES, F.J. and WHITEHOUSE, W.M., (1965). *The Gastrointestinal Tract*, 2nd ed. Year Book Medical Publishers, Chicago, p. 206.
- KERLEY, P., (1969). The Biliary Tract, In : *A Text Book of X-ray Diagnosis*, V. 4, 4th ed. Ed. Shanks, S.C., Kerley, P. W.B. Saunders Company, Philadelphia and Toronto, p. 532.
- KNUTSSON, F., (1933). On limy bile. *Acta Radiol.*, 14 : 453.
- KORNBLUM, K. and HALL, W.C., (1935). The roentgenologic significance of "milk of calcium" bile. *Amer. J. Roentgen.*, 33 : 611.
- MARQUIS, J.R. and DENSLER, J., (1970). The disappearing limy bile syndrome. *Radiology*, 94 : 311.
- PAUL, L.W. and JUHL, J.H., (1966). *The Essentials of Roentgen Interpretation*, 2nd ed., Hoeber Medical Division, Harper and Row, Publishers, New York and London, p. 366.
- SIMMONDS, H.T., JR., (1957). Milk of calcium bile in the common duct. *Amer. J. Roentgen.*, 78 : 1020.
- ROTHMAN, M.M., (1965). Anatomy and physiology of the gallbladder and bile ducts, In: *Gastroenterology*, V. 3, 2nd ed., Ed. Bockus, H.L., W.B. Saunders Company, Philadelphia and London, p. 578.
- WHITEHOUSE, W.M., (1967). Gallbladder Diseases, In : *Alimentary Tract Roentgenology*. V. 2, Ed. Margulis, A.R., Burhenne, H.J., The C.V. Mosby Company, Saint Louis, p. 949.