

RECOVERY AND GROWTH OF *HAPLORCHIS TAICHUI* (TREMATODA : HETEROPHYIDAE) IN CHICKS

Kanda Kumchoo¹, Chalobol Wongsawad¹, Jong-Yil Chai², Pramote Vanittanakom³
and Amnat Rojanapaibul¹

¹Department of Biology, Faculty of Science, Chiang Mai University, Chiang Mai, Thailand;
²Department of Parasitology and Tropical Medicine, Institute of Endemic Disease, College of
Medicine, Seoul National University, Seoul, Korea; ³Department of Pathology, Faculty of Medicine,
Chiang Mai University, Chiang Mai, Thailand

Abstract. An experimental study was performed to observe the recovery and growth of a minute intestinal fluke, *Haplorchis taichui* in chicks (*Gallus gallus domesticus*). Metacercariae of *H. taichui* were isolated from Jullien's mud carp, *Henicorhynchus siamensis*, which were collected in the Chiang Mai Province, Thailand. Two hundred metacercariae were orally force-fed to each chick. The intestine of the chicks were examined from day 1 to day 54 post-infection (PI). The incidence of infection was 84.9% (28/33) and the mean intensity was 19.9 (656/33), with the range 0-59. The worm recovery rate was the highest at day 11 PI (29.5%). On day 3 PI, mature adult worms were recovered and 1-200 eggs were observed in the uterus of the worms. The worms grew rapidly in the chicks and the genital organs were fully developed in 14 days. This parasite can survive in chicks up to day 48 PI. It is concluded that they are a suitable definitive host for infection with *H. taichui*.

INTRODUCTION

Haplorchis taichui is a heterophyid fluke. The adult can develop in the small intestines of birds and mammals, including humans (Faust and Nishigori, 1926; Yamaguti, 1958). In humans, *H. taichui* was first discovered from an autopsy of a man in northeastern Thailand (Manning *et al*, 1971). The distribution of this fluke depends on the presence of the first and the second intermediate hosts along with the eating habits of the local people (Radomyos *et al*, 1998). Humans acquire the infections from eating raw or undercooked freshwater fish, containing the metacercariae of *H. taichui*. Cyprinoid fish are important second intermediate hosts of this fluke. In Thailand, *H. taichui* is infected in many kinds of fish that are important as food and commerce (Kliks and Tantachamrun, 1974; Srisawangwong *et al*, 1997; Sukontason *et al*, 1999; Wongsawad *et al*, 2000). This worm has been reported as the predominant species of intestinal flukes recovered from people in northern Thailand (Pungpak *et al*, 1998; Radomyos *et al*, 1998).

Correspondence: Kanda Kumchoo, Department of Biology, Faculty of Science, Chiang Mai University, Chiang Mai 50200, Thailand.

Even though there is no documented report on the pathogenicity of *H. taichui*, it is generally known that heterophyid flukes irritate the intestinal mucosa and cause colicky pain and mucousy diarrhea, with production of excess amounts of mucus and superficial necrosis of the mucous coat (Beaver *et al*, 1984; Chai and Lee, 2002). It is also known that the eggs of this fluke can be deposited in the spinal cord or heart of man. Cases of human infections by other *Haplorchis* species have been reported in the Philippines (Africa *et al*, 1937a,b).

Little is known about the development of *H. taichui* in chicks. This study was performed to observe the recovery and growth of *H. taichui* in chicks (*Gallus gallus domesticus*). In addition, the sexual maturation and life span of *H. taichui* in chicks were examined, compared with a previous study in which chicks were considered as one of animal models for collecting adult worms.

MATERIALS AND METHODS

H. taichui metacercariae were obtained from Jullien's mud carp, *Henicorhynchus siamensis*, collected in the Mae Tang and Chom Thong districts in Chiang Mai Province, northern Thailand. Meta-

cercarial cysts were isolated by 1% acid pepsin. The digested material was passed through graded sieves to separate particles, rinsed in 0.85 % saline solution, then examined for the metacercarial stage under a stereomicroscope. For identification of *H. taichui*, the descriptions by Yamaguti (1958); Pearson (1964); Manning *et al* (1971) and Pearson and Ow-Yang (1982) were used.

Two week-old chicks (*Gallus gallus domesticus*), 33 in number, weighing approximately 84 g each, were used as the experimental definitive host. Two hundred encysted metacercariae, actively moving inside, were fed orally to each chick. Chicks were sacrificed daily at days 1-12 PI and every two days during days 14-54 to examine for parasites. The small intestine, was roughly divided into the duodenum, jejunum and ileum, and then opened in 0.85% saline solution. The mucosa of the intestine was scraped and rinsed, sedimented, and then examined under a stereomicroscope. The number of recovered worms was recorded. The collected flukes were fixed in 5% formalin under a cover glass, then stained with borax carmine or haematoxylin, counterstained with eosine and fast-green, dehydrated in alcohol series, cleared in xylol, and mounted in permount. The development and the morphological details of the worms were observed under a light microscope.

RESULTS

Worm recovery in chicks

Metacercariae of *H. taichui* developed into mature adults in chicks by 3 PI. Worms were recovered in the small intestines. On day 1 PI, one worm was found in the duodenum, but on day 2 PI and later the worms were predominantly recovered from the jejunum and ileum. After days 18 to 48 PI, the worms were found only in the ileum. The average worm recovery was highest on day 11 (29.5%), but it decreased after day 16 PI. Moreover, one active metacercaria was observed in the ileum at day 11 PI. During days 1-48 PI, the majority of worms were collected from the ileum (76.7%); a few from the jejunum (23.1%) and the least in the duodenum (0.2%). The incidence of infection was 84.9% (28/33) and the mean intensity was 19.9% (656/33). The parasite was found to survive in chicks until day 48 PI (Table 1).

Growth of *H. taichui* in chicks

The metacercariae of *H. taichui* were collected from the fish, *Henicorhynchus siamensis*. The newly excysted worm was elongated and oval in shape, 352 μm (320-390) long and 159 μm (140-175) wide. The ventrogenital sac was located ventrally in the middle region of the body and armed with 16 sclerites. Several organs showed rudimentary development, visible only in some specimens. A single testis, circular, 32.50 μm (30-40) in diameter was observed. The ovary was observed as a nearly circular or ovoid cell, situated posterior to the ventrogenital sac, approximately 22 μm (20-30) in diameter (Fig 1A). On day 1 PI, the worm differed a little from the metacercarial stage, especially in body size (Fig 1B). On the second day, visceral organs were more distinct and the uterus was recognized in some specimens (Fig 1C). Mature adults were observed on day 3 PI. The body size of adults was 504 μm (400-680) long and 216 μm (210-320) wide. The testis was enlarged, measuring 110 μm (90-150) in diameter. The seminal

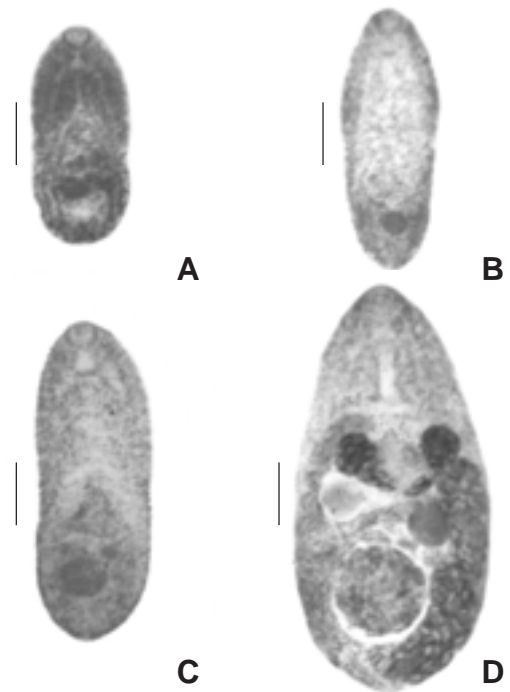


Fig1- Developmental stages of *H. taichui*: (A) an excysted metacercaria, (B) a 1- day old young worm, (C) a 2-day old young worm, (D) a 3-day young adult worm. Scale bar = 100 μm .

Table 1
Recovery rate of *Haplorchis taichui* from experimentally infected chicks during day 1 to day 54 post-infection.

Day after infection	Number of worms recovery from			Total	Worm recovery rate (%)
	Duodenum	Jejunum	Ileum		
1	1	24	20	45	22.5
2	0	17	17	34	17.0
3	0	17	21	38	19.0
4	0	12	37	49	24.5
5	0	7	33	40	20.0
6	0	4	26	30	15.0
7	0	1	31	32	16.0
8	0	2	46	48	24.0
9	0	0	39	39	19.5
10	0	3	30	33	16.5
11	0	22	37 ^a	59	29.5
12	0	2	29	31	15.5
14	0	2	39	41	20.5
16	0	7	28	35	17.5
18	0	0	19	19	9.5
20	0	0	10	10	5.0
22	0	0	16	16	8.0
24	0	0	10	10	5.0
26	0	0	23	23	11.5
28	0	0	1	1	0.5
30	0	0	2	2	1.0
32	0	0	3	3	1.5
34	0	0	3	3	1.5
36	0	0	2	2	1.0
38	0	0	2	2	1.0
40	0	0	8	8	4.0
42	0	0	0	0	0
44	0	0	0	0	0
46	0	0	2	2	1.0
48	0	0	2	2	1.0
50	0	0	0	0	0
52	0	0	0	0	0
54	0	0	0	0	0
Total metacercariae ^b	1	120	536	656	9.9

^aIncluding one of metacercaria; ^b200 metacercariae were given to each chick

vesicle was constricted in the middle part and divided into two parts. The ovary was circular, 52 μm (40-70) in diameter, and the seminal receptacle was greatly enlarged. Eggs were found in the uterus ranging from 1-200, 27.5 μm (25.0-28.75) long and 15.0 μm (12.5-16.25) wide. Vitellariae were well developed and confined to the area from the anterior border of the ovary to the posterior extremity

(Fig 1D).

The worms grew rapidly in the experimental chicks. Details of development were observed on days 0, 1, 2, 3, 7, 14, 22, 28, 36, 40 and 48 PI (Figs 2 and 3). The growth pattern of the worm was characterized by a prominent ascending curve during the early infection period and a slow-down after day 14 PI.

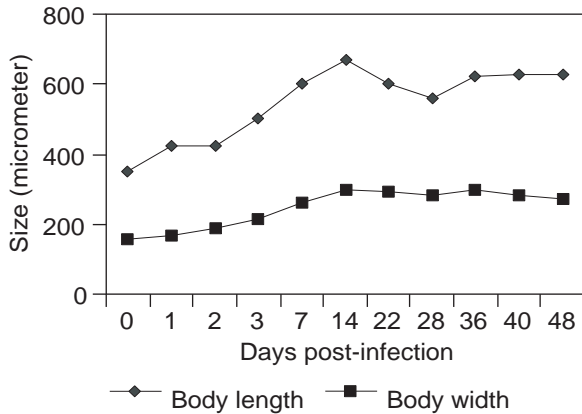


Fig 2- Development of the body size of *H. taichui* in experimental chicks (0 day = newly excysted metacercariae).

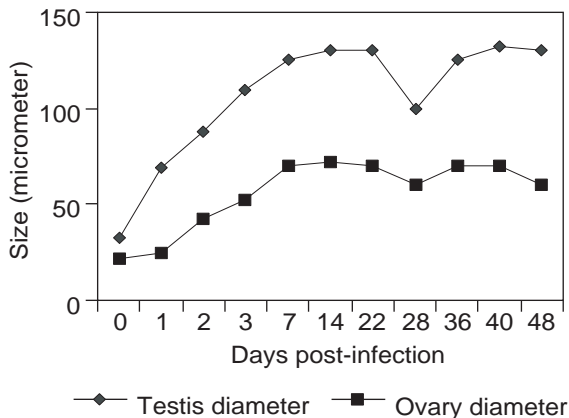


Fig 3- Development of genital organs of *H. taichui* after infection in chicks (0 day = newly excysted metacercariae).

DISCUSSION

Recovery and growth of *H. taichui* was observed in experimental chicks from day 1 to day 54 PI. On the third day, the eggs were found in the uterus of the worms, the same as in experimental mice (Sukontason *et al*, 2001). In this study, it was presented that the worms invaded in the jejunum during days 1-2 PI, but on day 3 PI and later they were mostly found in the ileum. However, they rapidly decreased after day 16 PI. Invasion of the fluke was demonstrated in

Monorchotrema taihokui and *Monorchotrema taichui* (*H. taichui*). The flukes invaded the upper part of the small intestine during the first period of infection, but when they matured, they were observed more in the middle and lower parts. (Faust and Nishigori, 1926). The flukes were excreted into the lumen of the intestinal canal along with mucus and other exudates, then they reattached to the intestine distally. In addition, one of the adults was found in the duodenum and one metacercaria in the ileum. It is suggested that it was excysted in the duodenum, but the micro-environment of this part of the intestine is not appropriate for the growth of the worm. The one metacercaria in the ileum, would have excysted and been excreted in the feces of the host. Excystation is dependant on a combination of external factors from the host and internal factors from the parasite along with the excystation site and the complexity of the cyst wall (Fried, 1994; Asanji and Williams, 1974).

The growth pattern of *H. taichui* was characterized by a prominent ascending curve during the early infection period and a slow-down after day 14 PI, which was similar to the growth curve of *Heterophyopsis continua* (Hong *et al*, 1990). This parasite survived in chicks until day 48 PI and a good yield of adults were obtained until day 16 PI. In mice the best yield was obtained only during the first 5 days (Sukontason *et al*, 2001). Probably the micro-environment in chicks was more suitable than that in mice for *H. taichui*, as is similar to other the heterophyid fluke, *Stellantchasmus falcatus* (Wongsawad *et al*, 1998). On the other hand, Chai (1979) suggested that the low worm recovery rate of *Metagonimus yokogawai* was possibly due to their short life span and the smaller size of mature worms. However, this study presented a better yield and a higher recovery rate than in mice, raising the possibility that the life span of *H. taichui* in chicks may be longer than in mice. Therefore, chicks can be used as a suitable definitive host for *H. taichui* to collect adult worms.

ACKNOWLEDGEMENTS

The research work was supported financially by the Royal Golden Jubilee PhD Program (PHD/

0081/2544). The authors wish to thank Dr Stephen Elliott, Mr Tanu Marayong, Mr Thanapon Yooyen, Mr Supap Saenphet and Mr Pralongyut Sripalwit for their assistance.

REFERENCES

- Africa CM, De Leon W, Garcia EY. Heterophyidiasis: V. Ova in the spinal cord of man. *Phil J Sci* 1937a; 62: 393-9.
- Africa CM, De Leon W, Garcia EY. Heterophyidiasis: VI. Two more cases of heart failure associated with the presence of eggs in sclerosed valves. *J PIMA* 1937b; 17: 605-10.
- Asanji MF, Williams MO. Studies on the excystment of trematode metacercariae *in vivo*. *J Helminthol* 1974; 48: 85-91.
- Beaver PC, Jung RC, Cupp EW. Clinical parasitology. Philadelphia: Lea and Febiger, 1984.
- Chai JY. Study on *Metagonimus yokogawai* (Katsurada, 1912) in Korea V. Intestinal pathology in experimentally infected albino rats. *Seoul J Med* 1979; 20: 104-17.
- Chai JY, Lee SH. Food-borne intestinal trematode infections in the Republic of Korea. *Parasitol Int* 2002; 51: 129-54.
- Faust EC, Nishigori M. The life cycles of two new species of heterophyidae, parasitic in mammals and birds. *J Parasitol* 1926; 13: 91-132.
- Fried B. Metacercarial excystment of trematodes. *Adv Parasitol* 1994; 33:91-144.
- Hong SJ, Lee SH, Chai JY, Seo BS. Recovery rate, growth and development of Heterophyopsis continua in experimental chicks. *Korean J Parasit* 1990; 28: 53-62.
- Kliks M, Tantachamrun T. Heterophyid (Trematoda) parasites of cats in north Thailand, with notes on a human case found at necropsy. *Southeast Asian J Trop Med Public Health* 1974; 5: 547-55.
- Manning GS, Lertprasert P, Watanasirmkit K, Chetty C. A description of newly discovered intestinal parasites endemic to northeastern Thailand. *J Med Assoc Thai* 1971; 54: 466-75.
- Pearson JC. A revision of the subfamily Haplorchinae Looss, 1899 (Trematoda: Heterophyidae). *Parasitology* 1964; 54: 601-76.
- Pearson JC, Ow-Yang CK. New species of *Haplorchis* from Southeast Asia, together with keys to the *Haplorchis*-group of Heterophyid trematodes of the region. *Southeast Asian J Trop Med Public Health* 1982; 13: 35-60.
- Pungpak S, Radomyos P, Radomyos B, Schelp FP, Jongsaksuntigul P, Bunnag D. Treatment of *Opisthorchis viverrini* and intestinal fluke infections with praziquantel. *Southeast Asian J Trop Med Public Health* 1998; 29: 246-9.
- Radomyos B, Wongsaraj T, Wilairatana P, et al. Opisthorchiasis and intestinal fluke infections in northern Thailand. *Southeast Asian J Trop Med Public Health* 1998; 29: 123-7.
- Srisawangwong T, Sithithaworn P, Tesana S. Metacercariae isolated from cyprinoid fishes in Khon Kaen district by digestion technic. *Southeast Asian J Trop Med Public Health* 1997; 28 (suppl): 224-6.
- Sukontason K, Piangjai S, Muangyimpong Y, Sukontason K, Methanitikorn R, Chaithong U. Prevalence of trematode metacercariae in cyprinoid fish of Ban Pao district, Chiang Mai Province northern Thailand. *Southeast Asian J Trop Med Public Health* 1999; 30: 365-70.
- Sukontason K, Sukontaso KL, Boonsriwong N, Chaithong U, Piangjai S, Choochote W. Development of *Haplorchis taichui* (Trematoda: Heterophyidae) in *Mus musculus* mice. *Southeast Asian J Trop Med Public Health* 2001; 32 (suppl): 43-7.
- Wongsawad C, Chariyahpongpun P, Namue C. Experimental host of *Stellantchasmus falcatus*. *Southeast Asian J Trop Med Public Health* 1998; 29: 406-9.
- Wongsawad C, Rojanapaibul A, Mhad-arehin N, et al. Metacercaria from freshwater fishes of Mae Sa Stream, Chiang Mai, Thailand. *Southeast Asian J Trop Med Public Health* 2000; 31: 54-7.
- Yamaguti S. Systema Helminthum. Vol I. The digenetic trematodes of vertebrates. Part I and II. New York: Interscience Publishing 1958.