

## CASE REPORT

### A THAI PATIENT WITH LEBER'S HEREDITARY OPTIC NEUROPATHY LINKED TO MITOCHONDRIAL DNA 14484 MUTATION

Wanicha Chuenkongkaew<sup>1</sup>, Patcharee Lertrit<sup>2</sup> and Rungrapa Suphavitai<sup>2</sup>

<sup>1</sup>Department of Ophthalmology, <sup>2</sup>Department of Biochemistry,  
Faculty of Medicine at Siriraj Hospital, Mahidol University, Bangkok, Thailand

**Abstract.** A young Thai male presented with bilateral visual loss and disc pallor. The 14484 mutation responsible for Leber's hereditary optic neuropathy (LHON) was identified on blood mitochondrial analysis. His visual loss was more severe than the visual loss described in Caucasian and Japanese patients and showed no improvement. He had no other identifiable mutations related to LHON nor any associated neurological disorder. This is the first case report of LHON with the 14484 mutation in a Thai patient.

Leber's hereditary optic neuropathy (LHON) is a maternally inherited ocular disorder associated with a mutation in mitochondrial DNA (mtDNA). It is characterized by acute or subacute bilateral painless, simultaneous or sequential loss of vision. The most common primary mutations are identified at nucleotide position (np) 11778, 3460 and 14484. The 11778 mutation is the only mutation that has so far been reported in Thai LHON patients (Lertrit *et al*, 1999; Chuenkongkaew *et al*, 2001). We present the first case of LHON with the 14484 mutation in a Thai patient.

A healthy 33-year-old Thai man developed visual loss in both eyes over 18 months. He had a history of a fall from a building site 7 years ago and he was also a heavy smoker. He has a brother and a sister who are both healthy. His pedigree is shown in Fig 1. Eye examination revealed a visual acuity of 1/60 in both eyes. The optic discs were pale bilaterally. The rest of the neurological examination was normal. A central visual field defect was detected in both eyes using Goldmann perimetry.

A 14484 mutation was detected in his blood mtDNA by restriction enzyme analysis and se-

quencing methods (Fig 2). His visual acuity remained stable throughout the 8 months follow-up period.

The LHON mtDNA point mutation at np 14484 was first described in 1992 (Johns *et al*, 1992). Unlike the mutations at np11778 and 3460, this mutation is identified in the NADH dehydrogenase subunit 6 gene which changes methionine-64 to valine. In Caucasian patients with LHON, the 14484 mutation has been reported in 10-15%, while the 11778 and 3460 mutations have been documented in 31-90% and 8-15% respectively (Newman, 1995). Although this mutation has been documented as a primary mutation, the combination of 11778 and 14484 has recently been reported (Riodan-eva *et al*, 1995; Brown *et al*, 2001).

The vision loss in patients with the 14484 mutation is usually less severe than in those with the 11778 and 3460 mutation. Approximately a half

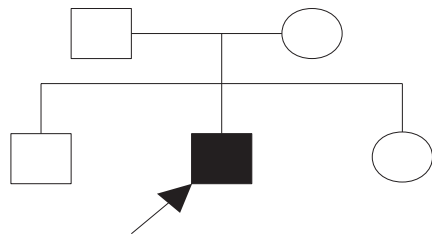


Fig 1—The pedigree of the patient.

Correspondence: Wanicha Chuenkongkaew, Department of Ophthalmology, Siriraj Hospital, Faculty of Medicine, 2 Prannok Road, Bangkok Noi, Bangkok 10700, Thailand.  
E-mail : siwck@mahidol.ac.th

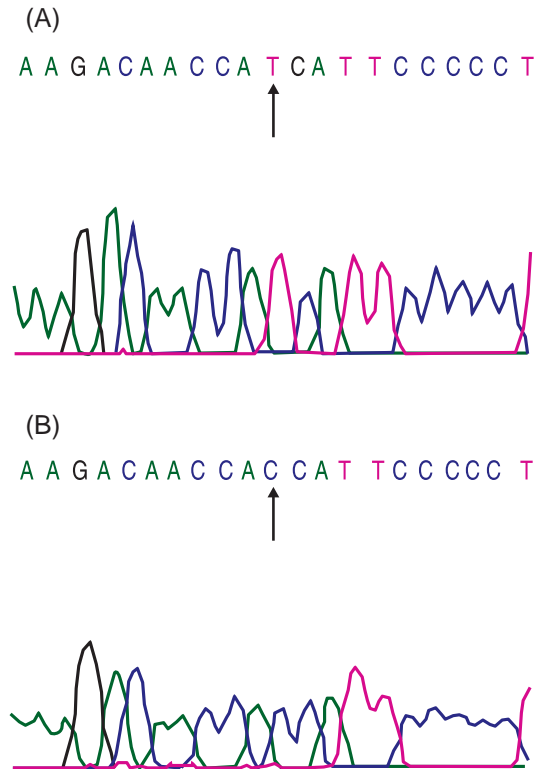


Fig 2—Chromatograms of the mitochondrial DNA (mtDNA) sequence covering nucleotide position (np) 14484 in the ND6 gene. (A) Wild type mtDNA sequence. (B) MtDNA sequence of the patient demonstrating the T to C mutation at np14484 (indicated by arrows).

of these patients have a greater likelihood of spontaneous recovery, particularly in the patients with an early onset of loss of vision (Johns *et al*, 1992; Mackey and Howell, 1992; Riordan-eva *et al*, 1995). Fifty percent of the patients with the 11778 mutation eventually become blind while only 30% of those with the 14484 mutation do so.

As a result of the blood mtDNA analysis, our patient was diagnosed with LHON with the 14484 mutation. In contrast to LHON with this mutation in both Caucasian and Japanese, our patient had severe visual loss and showed no improvement in final visual outcome (Johns *et al*, 1992; Mackey and Howell, 1992; Riordan-eva *et al*, 1995; Yamada *et al*, 1997). Moreover, a combination of 14484 and 4160 mutation and other neurological association have been occasionally described in Caucasians with LHON but not in our patient and also not in Japanese patients.

(Johns *et al*, 1992; Mackey and Howell, 1992; Oostra *et al*, 1994; Riordan-eva *et al*, 1995; Funalot *et al*, 1996; Yamada *et al*, 1997).

A 11778 mutation has been the only mutation which has so far been identified among Thais with LHON. However, this is the first reported case of a young Thai man with LHON with the 14484 mutation.

## REFERENCES

- Brown MD, Allen JC, van Stavern GP, Newman NJ, Wallace DC. Clinical, genetic, and biochemical characterization of a Leber hereditary optic neuropathy family containing both the 11778 and 14484 primary mutations. *Am J Genet* 2001; 104: 331-8.
- Chuenkongkaew WL, Lertrit P, Poonyathalang A, *et al*. Leber's hereditary optic neuropathy in Thailand. *Jpn J Ophthalmol* 2001; 45: 665-8.
- Funalot B, Ranoux D, Mas JL, Garcia C, Bonnefont JP. Brainstem involvement in Leber's hereditary optic neuropathy; association with the 14484 mitochondrial DNA mutation. *J Neurol Neurosurg Psychiatr* 1996; 61: 533-4.
- Johns DR, Neufeld MJ, Park RD. A ND-6 mitochondrial DNA mutation associated with Leber's hereditary optic neuropathy. *Biochem Biophys Res Commun* 1992; 187: 1551-7.
- Lertrit P, Ruangvaravate N, Trongpanich Y, Trnsumran A, Mungkornkarn C, Neungton N. Leber's hereditary optic neuropathy (LHON) with mitochondrial ND4 gene mutation (11778) in a Thai patient. *J Med Assoc Thai* 1999; 82: 59-64.
- Mackey D, Howell N. A variant of Leber hereditary optic neuropathy characterized by recovery of vision and by an unusual mitochondrial genetic etiology. *Am J Hum Genet* 1992; 51: 1218-28.
- Newman NJ. Neuro-ophthalmology and systemic disease-Part 1. *J Neuroophthalmol* 1995; 15: 109-21.
- Oostra RJ, Bolhuis PA, Wijburg FA, *et al*. Leber's hereditary optic neuropathy: correlation between mitochondrial genotype and visual outcome. *J Med Genet* 1994; 31: 280-6.
- Riordan-eva P, Sander MD, Govan GG, *et al*. The Clinical features of Leber's hereditary optic neuropathy defined by the presence of a pathogenic mitochondrial DNA mutation. *Brain* 1995; 118: 319-37.
- Yamada K, Mashima Y, Kigasawa K, Miyashita K, Wakakura M, Oguchi Y. High incidence of visual recovery among four Japanese patients with Leber's hereditary optic neuropathy with the 14484 mutation. *J Neuroophthalmol* 1997; 17: 103-7.