

# FOLLOW-UP ULTRASOUND PROTOCOL FOR NEONATES WITH MILD ANTENATAL HYDRONEPHROSIS

Anirut Pattaragarn<sup>1</sup>, Thanaporn Chaiyapak<sup>1</sup>, Ratchada Kitsommart<sup>1</sup>, Vitaya Titapant<sup>2</sup> and Achra Sumboonnanonda<sup>1</sup>

<sup>1</sup>Department of Pediatrics, <sup>2</sup>Department of Obstetrics and Gynecology, Faculty of Medicine Siriraj Hospital, Mahidol University, Bangkok, Thailand

**Abstract.** Postnatal ultrasound imaging is recommended for neonates with mild antenatal hydronephrosis. Imaging is commonly performed within the 1<sup>st</sup> week and at 1 month of age, although no consensus guideline has yet been established. The aim of this retrospective study was to compare antero-posterior renal pelvis diameter (APRPD) between these two time points in order to formulate a recommendation regarding ideal timing for postnatal ultrasound follow-up imaging in neonates with this disorder. Mild antenatal hydronephrosis was defined as APRPD within the range of 5-9.9 mm. Twenty-five neonates with 35 hydronephrotic kidneys were included. Median (range) APRPD at 1 week and 1 month of age was 6.7 (0-11) and 6.3 (0-10) mm, respectively. There was no significant difference between the two median APRPDs ( $p=0.10$ ); however, the correlation coefficient of 0.84 indicated a very good correlation. Of 35 kidneys, 22 had resolution of hydronephrosis within 1 month after birth. The two most common causes of the hydronephrosis were isolated antenatal hydronephrosis (46%) and transient and physiologic change (34%). During the mean±standard deviation follow-up period of 17.7±3 months, urinary tract infection was found in 4 patients (11%). No neonates in this study underwent any surgical procedures. Based on these results, postnatal ultrasound follow-up imaging in neonates diagnosed with mild antenatal hydronephrosis can be safely postponed until one month of age.

**Keywords:** hydronephrosis, antenatal hydronephrosis, congenital hydronephrosis, neonate

## INTRODUCTION

Pregnant women normally undergo prenatal ultrasound (US) screening to detect fetal abnormalities at 18-20 weeks of gestation (Davenport *et al*, 2013). Approximately 20-50% of fetal abnormalities involve the genitourinary system,

with 50% of those having hydronephrosis (Fefer and Ellsworth, 2006) for a prevalence ranging from 1-5% (Nguyen *et al*, 2010). Hydronephrosis is characterized by the dilatation of the pelvicalyceal system. This condition can result from congenital urological conditions, such as urinary tract obstruction, vesicoureteral reflux, or transient and physiologic change – all of which can be detected in utero. Hydronephrosis can spontaneously resolve after delivery or manifest later in life as urinary tract infection (UTI), hypertension, or even end-stage renal disease. Postnatal US imaging is, therefore, essential to establish a definitive diagnosis and to prevent further damage to the renal parenchyma.

---

Correspondence: Achra Sumboonnanonda, MD, Division of Nephrology, Department of Pediatrics, Faculty of Medicine Siriraj Hospital, Mahidol University, 2 Wanglang Road, Bangkok Noi, Bangkok 10700, Thailand.  
Tel: +66 (0) 2419 5660; Fax: +66 (0) 2419 5661  
E-mail: achara.sum@mahidol.ac.th

Most studies suggest that neonates with a diagnosis of moderate or severe hydronephrosis should undergo initial postnatal US imaging during the 1<sup>st</sup> week of life (Psooy and Pike, 2009; Nguyen *et al*, 2010; Davenport *et al*, 2013). However, no consensus has been reached among the nephrology community regarding the ideal timing of the initial postnatal US imaging and the frequency of subsequent follow-up US imaging in neonates with antenatal mild hydronephrosis (Liu *et al*, 2014; Vemulakonda *et al*, 2014). Based on data from postnatal US imaging performed at the age of 6 days, obstructive uropathy might be underestimated in patients with mild hydronephrosis (Clautice-Engle *et al*, 1995). Some studies recommend performing postnatal US imaging twice; specifically, within the 1<sup>st</sup> week of life and at the age of 3-6 weeks (Becker, 2009; Davenport *et al*, 2013). The first imaging aims to exclude the presence of important pathology that could require urgent surgery. The second imaging aims to detect obstructive uropathy that might be masked by transient oliguria during the 1<sup>st</sup> week of life. In mild antenatal hydronephrosis, if APRPD during the first month of life has not increased, the first US imaging in the postnatal follow-up should be performed at one month of age.

The aim of this study was to compare APRPD between the first week of life and one month of age in order to formulate a recommendation regarding ideal timing for postnatal ultrasound follow-up imaging in neonates with mild antenatal hydronephrosis.

## MATERIALS AND METHODS

### Study design and study subjects

The protocol for this study was approved by the Siriraj Institutional Review Board (SIRB), Faculty of Medicine Siriraj Hospital, Mahidol University. This retrospective study included cases of mild antenatal hydronephrosis that were detected in pregnant women who underwent ultrasound (US) imaging by an obstetrician at

the Maternal-Fetal Medicine Unit, Department of Obstetrics and Gynecology, Siriraj Hospital, during the 1 January 2000 to 31 December 2010 study period.

Serial prenatal US imaging was performed in cases with APRPD greater than 5 mm. All neonates with a diagnosis of mild antenatal hydronephrosis detected after 28 weeks of gestation were included. Mild antenatal hydronephrosis was defined as APRPD in the range of 5.0-9.9 mm (Wollenberg *et al*, 2005). Stillbirth, neonatal death, and neonates without postnatal US at one week and one month of life were excluded.

Postnatal US imaging was performed at least twice by a radiologist using a Philips iU22 ultrasound system (Philips Healthcare, Bothell, WA). The first imaging was performed within the 1<sup>st</sup> week of life. The second imaging was performed at one month of age, even if hydronephrosis was spontaneously resolved during the 1<sup>st</sup> week of life. Transient and physiologic change was defined as hydronephrosis that resolved during the first week of life. Idiopathic antenatal hydronephrosis was defined as hydronephrosis with no identifiable urinary tract abnormalities, including obstruction and vesicoureteral reflux. Voiding cystourethrogram (VCUG) was only performed in neonates that had UTI or progressive hydronephrosis.

### Statistical analysis

The sample size was determined based on data from our pilot study evaluating postnatal APRPD. For this determination, we hypothesized that APRPD within the 1<sup>st</sup> week of life and at 1 month of age were not different. With a 2-sided 5% significance level and 90% power, a sample size of 27 neonates was calculated. Paired *t*-test or Wilcoxon signed-rank test was used to analyze differences in APRPDs. Pearson's correlation coefficient or Spearman's rank correlation coefficient was used to study association between APRPD within the 1<sup>st</sup> week of life and APRPD at 1 month of age.

A two-sided  $p$ -value  $<0.05$  was regarded to be statistically significant. A correlation coefficient of greater than 0.8 indicated a strong relationship between variables. Kaplan-Meier survival analysis was used to evaluate resolution of mild hydronephrosis. Results are expressed as median and range, mean  $\pm$  standard deviation (SD), or number and percentage. SPSS® Statistics version 16.0 (SPSS, Chicago, IL) for Windows XP® (Microsoft Corporation, Redmond, WA) was used for calculations and statistical analysis.

## RESULTS

A total of 25 neonates, including 22 males and 3 females, were recruited. Mild antenatal hydronephrosis was found in 35 (70%) kidneys. Twenty-two neonates (88%) had bilateral hydronephrosis. Of these, 10 neonates had bilateral mild hydronephrosis, while 12 had mild hydronephrosis in one kidney and moderate or severe hydronephrosis in the other. For the remaining 3 patients, hydronephrosis was detected in 2 neo-

nates (8%) in the right kidney and in 1 neonate (4%) in the left kidney.

The mean age of the mothers was 25 years (range: 15-41). The average gestational age was 38.5 weeks (range: 34-41). Mean birth weight of neonates was 3,180 grams (range: 2,000-4,000). Twenty-four neonates (96%) were born with appropriate weight for the gestational age. No neonates had coexisting congenital anomalies (Table 1). The mean duration of postnatal follow-up was 17.7 months (range: 1–111.5).

Postnatal evaluation revealed idiopathic antenatal hydronephrosis in 16 kidneys (46%), transient and physiologic change in 12 kidneys (34%), extrarenal pelvis in 5 kidneys (14%), and bilateral ureteropelvic junction obstruction (UPJO) in two neonates (6%) (Table 2). The neonate with UPJO had a prenatal APRPD of 9.5 mm in both kidneys. At the age of 2 months, the left UPJO spontaneously resolved and the right kidney had persistent mild hydronephrosis with an APRPD of 9 mm.

Table 1  
Perinatal clinical and demographic characteristics of neonates.

Characteristics	N=25
Gestational age (wk), mean $\pm$ SD	38.5 $\pm$ 1.5
Birth weight (g), mean $\pm$ SD	3,180 $\pm$ 530
Length (cm), mean $\pm$ SD	50.0 $\pm$ 2.6
Gender, <i>n</i> (%)	
Male	22 (88)
Female	3 (12)
Apgar scores, median (min-max)	
1 min	9 (7-10)
5 min	10 (9-10)
Birth weight relative to GA, <i>n</i> (%)	
Small for GA	0 (0)
Appropriate for GA	24 (96)
Large for GA	1 (4)

SD, standard deviation; GA, gestational age.

Of 35 kidneys, 22 resolved spontaneously before 1 month of age (Fig 1). Hydronephrosis resolved in 12 kidneys (34.3%) within the 1<sup>st</sup> week of life, and the other 10 kidneys (28.6%) returned to normal by 1 month of age. The remaining 13 kidneys that still had hydronephrosis at one month of age had median APRPDs of 6.7 mm during the 1<sup>st</sup> week of life and 6.3 mm at one month of age. There was no significant difference between the median APRPD during the 1<sup>st</sup> week of life and at one month of age ( $p=0.10$ ). A correlation coefficient of 0.84 indicated a very good correlation between the APRPDs at these two time points (Fig 2). There

was an increase in APRPD in one neonate from 4.2 mm in the 1<sup>st</sup> week of life to 6.3 mm at one month of age. He was diagnosed as having idiopathic antenatal hydronephrosis. There was no urinary tract infection, hypertension, or renal failure found in this patient. The last US imaging at the age of 6 months showed a reduction in APRPD to 5 mm.

### DISCUSSION

Antenatal hydronephrosis has been increasingly reported over the past 20 years due to the increasing use of prenatal ultrasound (US)

Table 2  
Etiology of mild antenatal hydronephrosis from 35 kidneys.

Etiology	n (%)
Idiopathic antenatal hydronephrosis	16 (46)
Transient and physiologic change	12 (34)
Extrarenal pelvis	5 (14)
Ureteropelvic junction obstruction	2 (6)

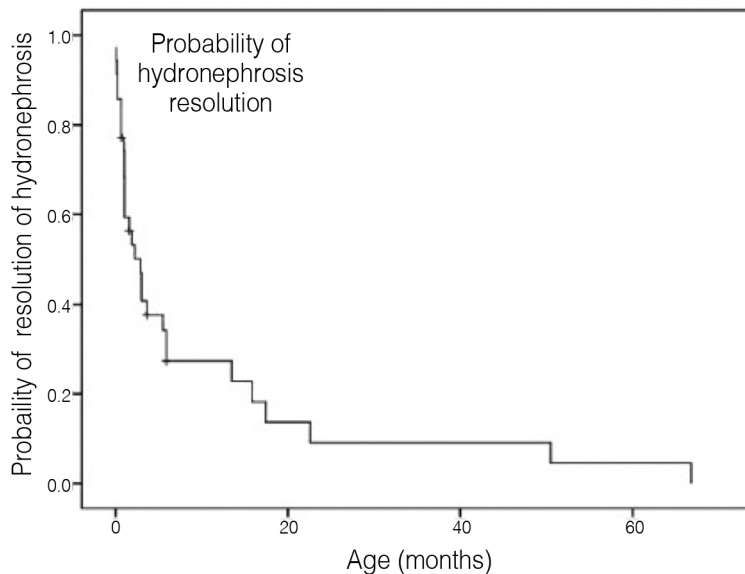


Fig 1– Probability of hydronephrosis resolution by age.

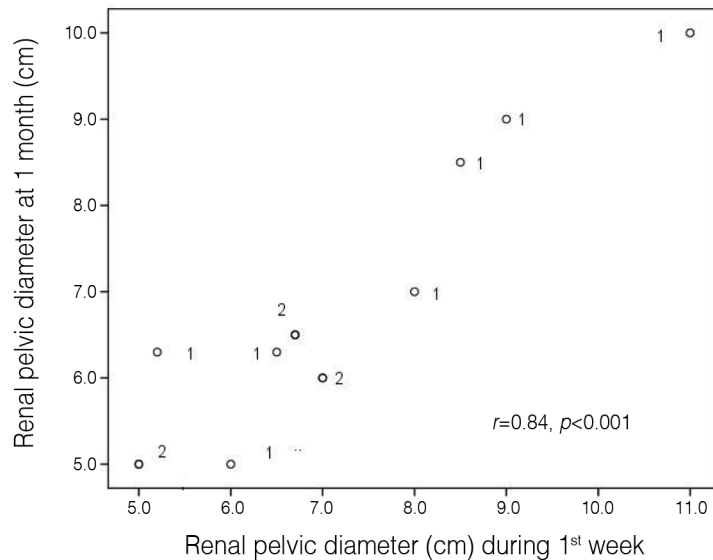


Fig 2– Correlation between renal pelvic diameter measured by ultrasonography during the 1<sup>st</sup> week of life and at 1 month of age.

screening in pregnant women, which facilitates early recognition of conditions and complications before symptoms develop. Some studies have suggested that neonates with moderate or severe antenatal hydronephrosis should have their first postnatal US imaging within the 1<sup>st</sup> week of life, and then undergo further imaging studies that include VCUG and diuretic renogram (Yiee and Wilcox, 2008; Psooy and Pike, 2009). The first postnatal US imaging during the 1<sup>st</sup> week is usually performed after 48 hours of life, which is when transient oliguria normally develops (de Bruyn and Gordon, 2001; Sinha *et al*, 2013). However, the ideal time point for the first postnatal US in neonates diagnosed with mild antenatal hydronephrosis remains a highly controversial issue. One study suggested delaying the first US until the age of 6 weeks (Anderson *et al*, 2010), with others suggesting that the first US should be performed at the age of 2-3 weeks (Estrada, 2008; Davenport *et al*, 2013). Other studies, however, recommended that the first US imaging be performed within the 1<sup>st</sup> week of life regardless of severity, and

then be repeated at the age of 3-6 weeks, even if the first US yields normal results or shows mild hydronephrosis in order to avoid misinterpretation due to transient oliguria in the postnatal period (Becker, 2009; Psooy and Pike, 2009; Liu *et al*, 2014). Other studies reported that postnatal US imaging during the 1<sup>st</sup> week of life is not sufficient to verify the absence of pathology (Lidefelt and Herthelius, 2008; Sinha *et al*, 2013).

Hydronephrosis continued to persist in 13 of 35 kidneys in our study at one month of age. In this group, the average size of APRPD was almost unchanged at 1 month, as compared to the APRPD measured within the 1<sup>st</sup> week of life. In the other 22 kidneys, mild hydronephrosis resolved spontaneously by the age of 1 month. The resolution rate of hydronephrosis by 1 month of age was previously reported to vary from 25-60% (Signorelli *et al*, 2005; Merlini *et al*, 2007). One patient with transient and physiologic change in our study developed some progression of hydronephrosis in the 1<sup>st</sup> month of life, which later regressed. Similarly,

Tombesi and Alconcher (2012). reported that 2 of 160 cases with mild hydronephrosis had some progression of disease. Additionally, hydronephrosis could reappear after spontaneous postnatal improvement in some cases, even in cases with mild hydronephrosis (Matsui *et al*, 2008). It was suggested that monitoring by US imaging should be conducted periodically even though prenatally detected hydronephrosis was not demonstrated by postnatal US.

Almost all neonates in this study were male and most had bilateral hydronephrosis. Most of our cases with mild antenatal hydronephrosis were benign and were not associated with other urinary tract abnormalities. Consistent with previous reports, the two most common types of antenatal mild hydronephrosis were idiopathic antenatal hydronephrosis, and transient and physiologic change that may result from fetal ureteric folds, increased fetal urine output, or inadequate maturation of the ureteropelvic or vesicoureteric junction (de Bruyn and Gordon, 2001; Ahmad and Green, 2005; Coelho *et al*, 2007). Of the 25 patients we evaluated, 11% developed UTI within the 1<sup>st</sup> year of life, which was similar to findings from previous studies (Coelho *et al*, 2007; Tombesi and Alconcher, 2012). None of our patients experienced hypertension, renal failure, or surgical interventions, which also corresponded with previously reported findings (Ahmad and Green, 2005; Coelho *et al*, 2007; Tombesi and Alconcher, 2012).

Limitations of this study include a small number of patients and incomplete follow-up in some patients. Given that most cases of mild antenatal hydronephrosis in this study were of the transient and physiologic change type, VCUG would be performed only in the neonates with a history of UTI or in those who had an increase in APRPD during the follow-up period (Psooy and Pike, 2009). Nevertheless, parents must be informed about the possibility of vesicoureteral reflux and the need of urinalysis in cases of unexplained fever.

In conclusion, mild antenatal hydronephrosis had a high rate of spontaneous resolution among neonates in this study. However, APRPD in cases of persistent hydronephrosis was mostly unchanged within the 1<sup>st</sup> month of life. Mild antenatal hydronephrosis is relatively benign and rarely requires surgical intervention. Our findings suggest that postnatal ultrasound follow-up imaging in neonates diagnosed with mild antenatal hydronephrosis can be safely postponed until one month of age. This follow-up evaluation strategy will lower medical costs and reduce the stress experienced by neonates that have to undergo these investigations.

## ACKNOWLEDGEMENTS

The authors gratefully acknowledge Julaporn Pooliam for statistical analysis.

## CONFLICTS OF INTEREST

The authors hereby declare no personal or professional conflicts of interest regarding any aspect of this study.

## REFERENCES

- Ahmad G, Green P. Outcome of fetal pyelectasis diagnosed antenatally. *J Obstet Gynaecol* 2005; 25: 119-22.
- Anderson NG, Fischer J, Leighton D, Hector-Taylor J, McEwing RL. Management in children of mild postnatal renal dilatation but without vesicoureteral reflux. *Pediatr Nephrol* 2010; 25: 477-83.
- Becker AM. Postnatal evaluation of infants with an abnormal antenatal renal sonogram. *Curr Opin Pediatr* 2009; 21: 207-13.
- Clautice-Engle T, Anderson NG, Allan RB, Abbott GD. Diagnosis of obstructive hydronephrosis in infants: comparison sonograms performed 6 days and 6 weeks after birth. *AJR Am J Roentgenol* 1995; 164: 963-7.

- Coelho GM, Bouzada MC, Pereira AK, *et al.* Outcome of isolated antenatal hydronephrosis: a prospective cohort study. *Pediatr Nephrol* 2007; 22: 1727-34.
- Davenport MT, Merguerian PA, Koyle M. Antenatally diagnosed hydronephrosis: current postnatal management. *Pediatr Surg Int* 2013; 29: 207-14.
- de Bruyn R, Gordon I. Postnatal investigation of fetal renal disease. *Prenat Diagn* 2001; 21: 984-91.
- Estrada CR, Jr. Prenatal hydronephrosis: early evaluation. *Curr Opin Urol* 2008; 18: 401-3.
- Fefer S, Ellsworth P. Prenatal hydronephrosis. *Pediatr Clin North Am* 2006; 53: 429-47, vii.
- Lidefelt KJ, Herthelius M. Antenatal hydronephrosis: infants with minor postnatal dilatation do not need prophylaxis. *Pediatr Nephrol* 2008; 23: 2021-4.
- Liu DB, Armstrong WR, 3rd, Maizels M. Hydronephrosis: prenatal and postnatal evaluation and management. *Clin Perinatol* 2014; 41: 661-78.
- Matsui F, Shimada K, Matsumoto F, Takano S. Late recurrence of symptomatic hydronephrosis in patients with prenatally detected hydronephrosis and spontaneous improvement. *J Urol* 2008; 180: 322-5.
- Merlini L, Parvex P, Anooshiravani-Dumont M, Girardin E, Hanquinet S. Postnatal management of isolated mild pelvic dilatation detected in antenatal period. *Acta Paediatr* 2007; 96: 1131-4.
- Nguyen HT, Herndon CD, Cooper C, *et al.* The society for fetal urology consensus statement on the evaluation and management of antenatal hydronephrosis. *J Pediatr Urol* 2010; 6: 212-31.
- Psooy K, Pike J. Investigation and management of antenatally detected hydronephrosis. *Can Urol Assoc J* 2009; 3: 69-72.
- Signorelli M, Cerri V, Taddei F, Groli C, Bianchi UA. Prenatal diagnosis and management of mild fetal pyelectasis: implications for neonatal outcome and follow-up. *Eur J Obstet Gynecol Reprod Biol* 2005; 118: 154-9.
- Sinha A, Bagga A, Krishna A, *et al.* Revised guidelines on management of antenatal hydronephrosis. *Indian Pediatr* 2013; 50: 215-31.
- Tombesi MM, Alconcher LF. Short-term outcome of mild isolated antenatal hydronephrosis conservatively managed. *J Pediatr Urol* 2012; 8: 129-33.
- Vemulakonda V, Yiee J, Wilcox DT. Prenatal hydronephrosis: postnatal evaluation and management. *Curr Urol Rep* 2014; 15: 430.
- Wollenberg A, Neuhaus TJ, Willi UV, Wisser J. Outcome of fetal renal pelvic dilatation diagnosed during the third trimester. *Ultrasound Obstet Gynecol* 2005; 25: 483-8.
- Yiee J, Wilcox D. Management of fetal hydronephrosis. *Pediatr Nephrol* 2008; 23: 347-53.